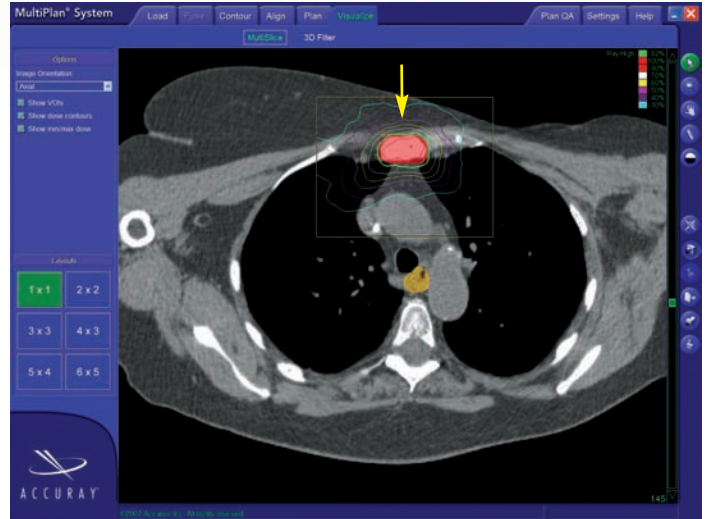
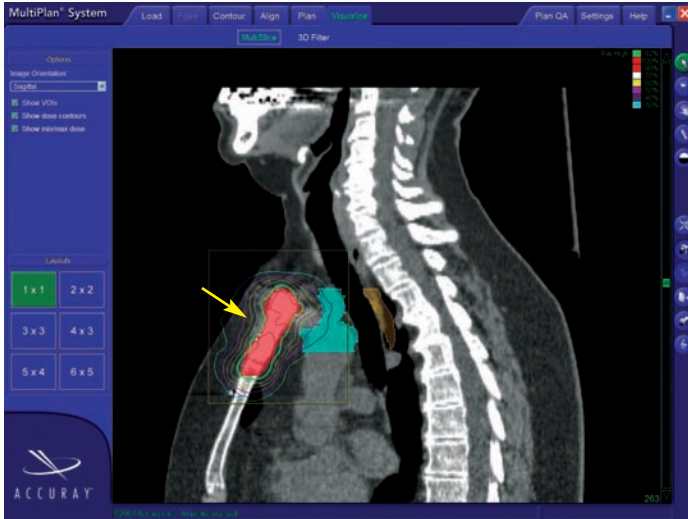


CASE STUDY

Treatment of Painful Sternal Metastasis from Breast Cancer



Patient History

A 69-year-old female with a history of breast cancer underwent a modified radical mastectomy for Stage II disease (ER positive, PR negative, Her2 positive) in 1994. Thirteen years later, she developed sternal pain and a PET scan revealed a focal area of hypermetabolic activity in the manubrium of the sternum that had increased in size and intensity of uptake when compared to the prior PET done 6 months earlier. A biopsy also confirmed metastatic disease.

CyberKnife® Advantage

The patient was referred for a surgical opinion. Surgical excision was felt to be inappropriate. Other options included conventional radiation therapy consisting of 33 treatments over approximately 6-7 weeks or CyberKnife stereotactic radiosurgery for curative intent. The patient opted for CyberKnife radiosurgery, a radiation treatment modality in which conformality and explicit control of homogeneity is possible with only five (5) treatments.

Treatment

In December 2007, four bone fiducial markers were implanted by her thoracic surgeon in the manubrium one (1) week prior to her planning CT scan. The patient was immobilized in an Alpha cradle. A 25 mm collimator was used to treat the 3.9 cc GTV (Gross Tumor Volume) with 3500 cGy prescribed to the 82% isodose line in five (5) fractions using 142 beams.

Outcome & Follow-Up

A PET/CT taken 4 months after CyberKnife treatment revealed no evidence of disease. The patient reported no side effects or complications from the treatment and was able to return to her normal daily activities and routine immediately after treatment.

If you would like your patient case reviewed at our weekly case conference, call 337-289-8070.

CyberKnife Center- Louisiana Team:

Radiation Oncologist: David K. Caletri, M.D.
Thoracic Surgeon: Richard Dearman, M.D.
Medical Physicist: Meyer Heiman, M.S.

